

10 Best Kept Secrets for Treating Cats with Cancer

Gregory K. Ogilvie
 Diplomate ACVIM (Internal Medicine, Oncology)
 Diplomate ECVIM-CA (Oncology)

UCSD
 UC San Diego
 Moores Cancer Center

Angel Care



Kitty Cat Secrets

- 1. Less restraint is best restraint.
- 2. Cats are not small d*gs.
- 3. Cats are made of steel.
- 3. Evil cats live forever.
- 4. Clients lie if they say they give all meds
- 5. Most cats with cancer are anemic

© GK Ogilvie 2022




Kitty Cat Secrets

6. Clients Believe

- ~50% of Cats with Cancer are in Pain
 (J Am Vet Med Assoc. 2005 5;226(8):1354)
- Rarely Show Clinical Signs
- Prevention is Vital

© GK Ogilvie 2022





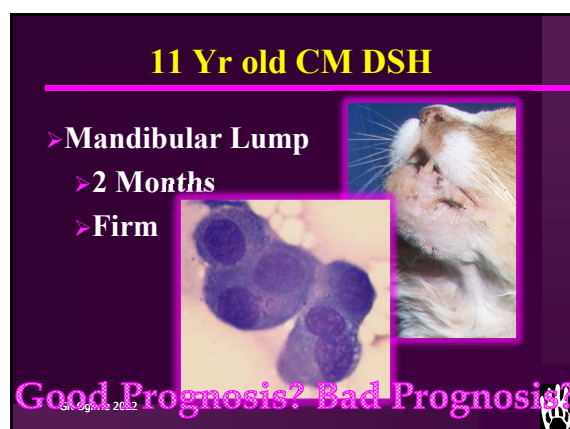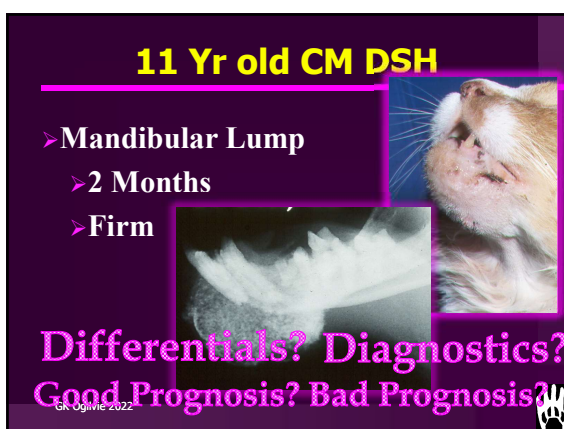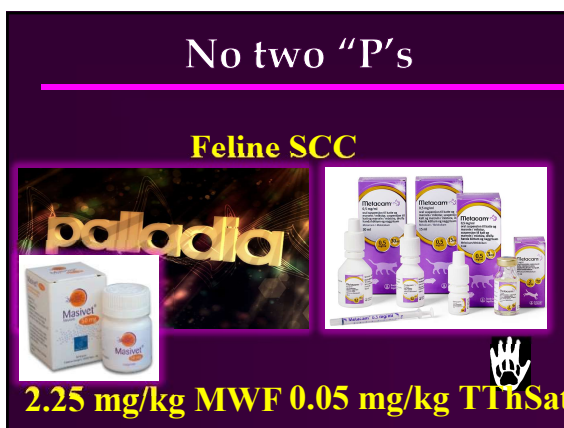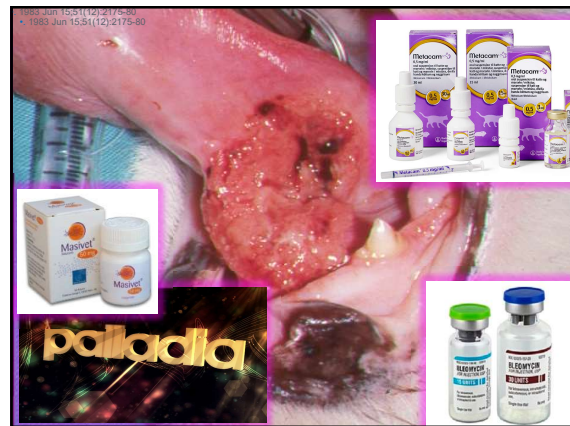Differentials? Diagnostics?
Good Prognosis? Bad Prognosis?

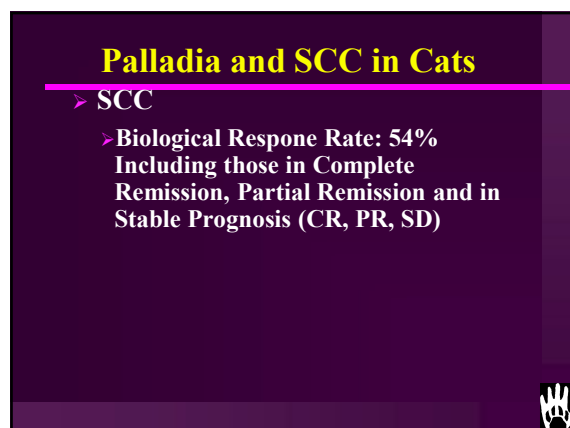
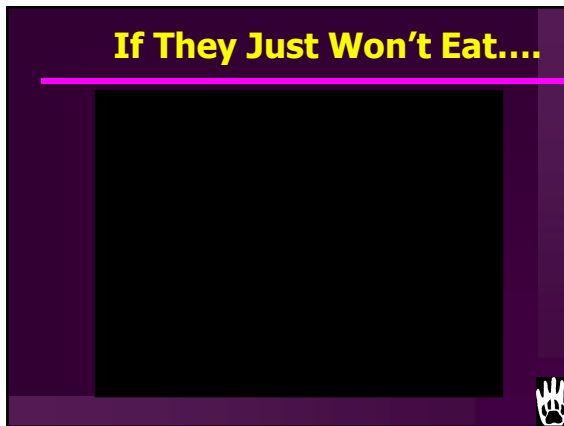



Oral Squamous Cell Carcinoma

- Esophagosomy tube
- Bleomycin
- Meloxicam or Piroxicam + Palladia







Oral Squamous Cell Carcinoma

- Esophagosomy tube
- Bleomycin
- Meloxicam or Piroxicam + Palladia or Masitinib
- Mandibulectomy +/- Radiation



Oral Squamous Cell Carcinoma

Question:

- What is the MOST important prognostic factor for ORAL SCC?



Kitty Cat Secrets

- 7. Cats with oral SCC with bone involvement have a better prognosis.
- 8. Cats with oral SCC of the maxilla generally do better than those of the mandible.
- 9. Cats with sublingual SCC generally have a poor prognosis.

GK Ogilvie 2022

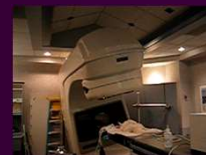

Oral Squamous Cell Carcinoma



Carboplatin, Radiation: Oral SCC

- Median Survival for all Cats was 163 Days
- Tonsil SCC Best: Median Survival: 724 days



J Vet Intern Med. 2011;25(3):504-10

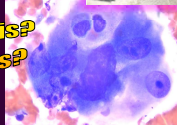


7 Yr Old SF DSH

➤ 6 Months:
"Sore on
Nose"

➤ Refractory
to Steroid Rx

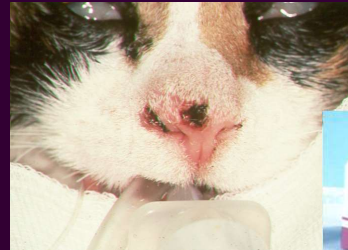Good Prognosis?
Bad Prognosis?



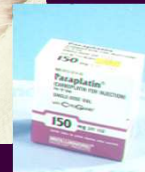GK Ogilvie 2015



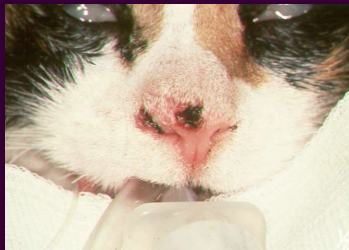Intralesional Carboplatin



1.5 mg/cm³



Imiquod Cream

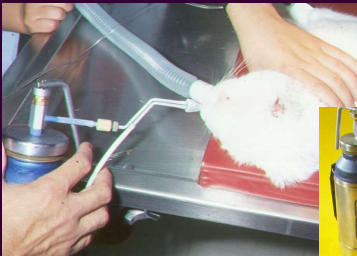

Aldara™ (imiquimod) Cream, 5%

- Anti-viral, anti-tumor activity
 - ❖ Induces transcription and translation of multiple cytokines
 - ❖ Imiquimod induces IL2, IL12, interferons alpha and gamma



JAAHA 33[4]:329-332 1997

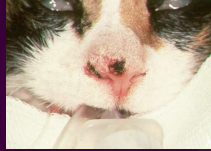

Surgery



Cutaneous Squamous Cell Carcinoma

- Small, Superficial
 - Cryotherapy (<1 cm)
 - Imiquimod Cream
- Larger, Moderately Invasive
 - Surgery
 - Radiation
 - Intralesional Chemo
- Invasive, Large
 - Radiation

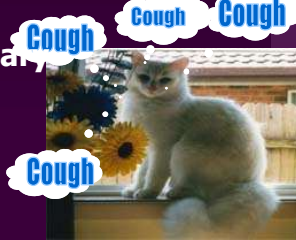

GK Ogilvie 2015



12 Yr Old Female DLH

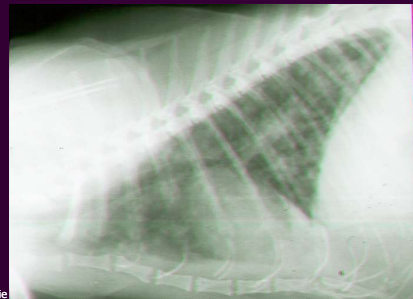
- 0.5 cm Mammary Mass
- Ulcerated
- "Fixed"
- Progressive Cough



GK Ogilvie 2022



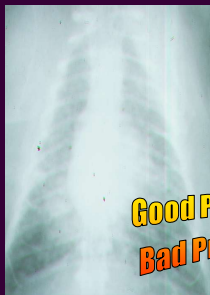12 Yr Old Female DLH



GK Ogilvie



12 Yr Old Female DLH

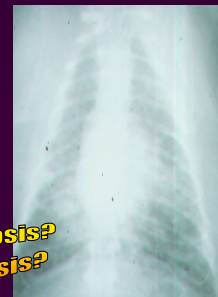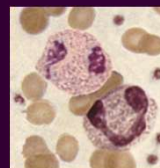


Good Prognosis?
Bad Prognosis?

GK Ogilvie 2022



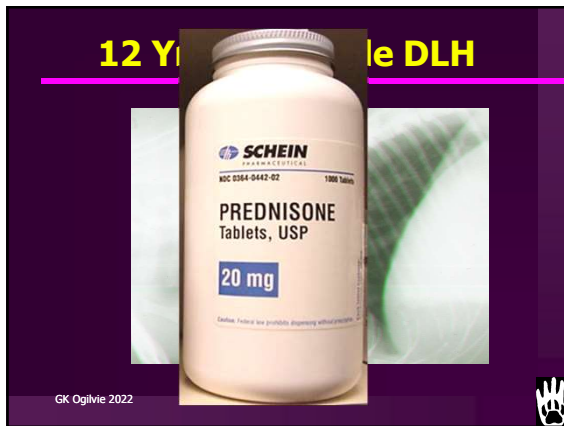12 Yr Old Female DLH



Good Prognosis?
Bad Prognosis?

GK Ogilvie 2022





Question!

- What is the single MOST important clinical finding for determining survival in cats with mammary tumors?
 - 1. Presence of ulceration
 - 2. Number of tumors
 - 3. Location of tumors
 - 4. Size of tumors

Secrets of Kitty Cancer

MGT's! Size!!!

- <2cm-2 yrs
- 2-3 cm-1 yr
- >3cm-6 mo

GK Ogilvie 2022

Mammary Adenocarcinoma:

1 mg/kg q3 wks X5

Bilateral vs Unilateral Mastectomy

- 107 client-owned cats
 - Complications: 19% Unilateral, 35.7% Staged Bilateral, 40.6% Bilateral Mastectomy
 - Median Progression-Free Survival Time Longer for Bilateral (542 days) vs Unilateral Mastectomy (289 days).

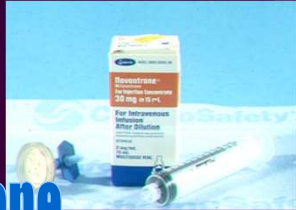J Am Vet Med Assoc. 2018 1;252(11):1393-1401

Mammary Adenocarcinoma: DFI

- Surgery: 270 Days
- Surgery + Dox: 226 Days
- Surgery + Dox/Meloxicam/Cyclophosphamide: 372 Days
- Vet Comp Oncol 2021 Dec;19(4):714-723.

Mammary Adenocarcinoma

Mitoxantrone



Kitty Cat Secrets

- 10. Cats with metastases rarely cough til end stage
- 11. Size of mammary tumor is prognostic
- 12. Doxorubicin, Mitoxantrone may be helpful
- 13. Docosahexaenoic Acid



Kitty Cat Secrets

- Respiratory system
 - 14. Dyspnic cat=Severe pathology
 - 15. Radiographs best tool for respiratory abnormalities. Use extreme caution!
 - 16. Severe dyspnea + normal rads = abnormalities = functional airway Prognosis (e.g., asthma, rarely thromboemboli). Donuts!
 - 17. Collapse of right middle lung common sequel, chronic lung Prognosis.

GK Ogilvie 2022



9 Yr Old, CM DSH

- Abdominal Enlargement
- Anorexia
- Splenomegaly
- CBC, Profile Normal



GK Ogilvie 2022



9 Yr Old, CM DSH

- Questions?
- Problem List/Differentials?
- Tests/Procedures?
- Initial Therapy?

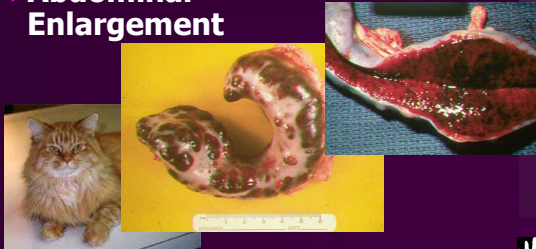

GK Ogilvie 2022



9 Yr Old, CM DSH

➤ Abdominal Enlargement



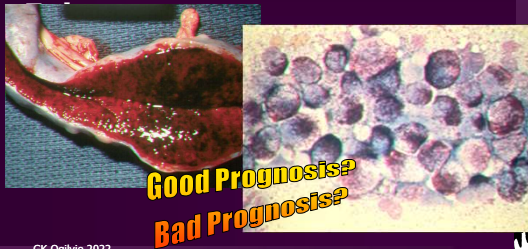Question!

➤ What is the **MOST COMMON** cause of splenic Prognosis causing splenomegaly in the cat?

- 1. Immune Mediated Prognosis
- 2. Hemangiosarcoma
- 3. Lymphoma
- 4. Mast Cell Tumor

9 Yr Old, CM DSH

➤ Abdominal



GK Ogilvie 2022

MCT's: Great Impostors!

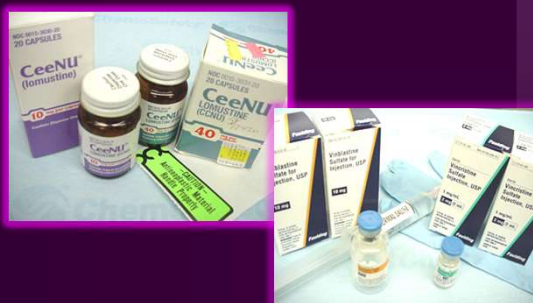455 Cats with Splenic Prognosis
MCT #1 Cause!!!!
Resection: Survival 2 Yrs!!!



J Am Vet Med Assoc 201[5]:773-776 Sep 1'92

GK Ogilvie 2022

Feline Mast Cell Tumors



Mast Cell Tumors



Secrets of Kitty Cancer

18. Splenic
MCT's in the Cat:
Not that Bad!



GK Ogilvie 2022



12 Year Old, Female DSH

- Ulcerated, Fixed Mass
- First Mammary Gland 3 Week Duration



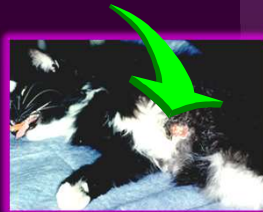Differentials? Diagnostics?
Good Prognosis? Bad Prognosis?



12 Year Old Female DSH

Important Questions:

- Preoperative vs Intraoperative?
- FNA vs Tissue
- Excisional vs Incisional



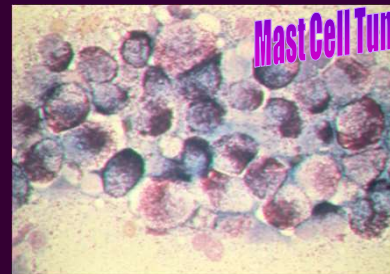12 Year Old Female DSH



12 Year Old Female DSH



12 Year Old Female DSH



Mast Cell Tumor!



MCT's: Great Impostors!

32 Cats: Cutaneous MCT's

- Benign Biological Behavior
- Surgery: Curative!

Good Outcome!

J Am Anim Hosp Assoc 34[4]:281-284 Jul/Aug'98





Injection Site Sarcoma




Good Prognosis? Bad Prognosis?



© GK Ogilvie 2015

FISS/STS: Critical Points

- **Record** anatomic location, shape, size
- **Manage** every mass as if malignant
- **Biopsy** mass prior to surgical excision
- **Stage** patient prior to surgical excision
- **Excise** deep/wide, submit for histopath

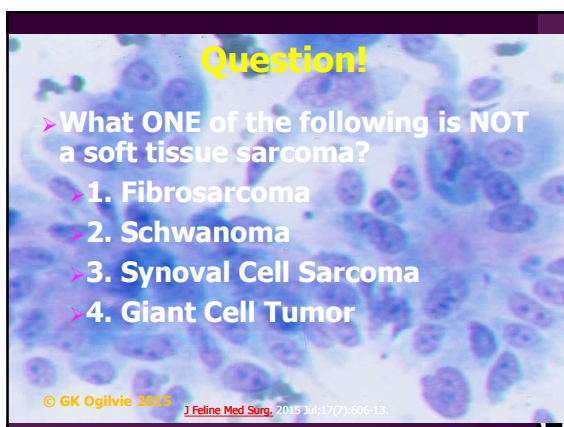


Question!

➤ What ONE of the following is NOT a soft tissue sarcoma?

1. Fibrosarcoma
2. Schwannoma
3. Synovial Cell Sarcoma
4. Giant Cell Tumor

© GK Ogilvie 2015 J Feline Med Surg, 2015 Jul;17(7):606-13.




Fibrosarcoma
Neurofibrosarcoma
Giant Cell Tumor
Soft Tissue Sarcoma
Fibroma
Schwannoma
Hemangiopericytoma

© GK Ogilvie 2015

© GK Ogilvie 2015

Soft Tissue Sarcomas

What's the Cause?



J Feline Med Surg, 2015 Jul;17(7):606-13.

FISS vs Soft Tissue Sarcomas

- Unique Etiology Hypothesized
- Unique Histopathology
- More Aggressive Locally
- Higher Rate of Metastases
 - Lung>Nodes>Organs



© GK Ogilvie 2016 *J Feline Med Surg*, 2015 Jul;17(7):606-13.

Hypothesized FISS Causation

The most accepted hypothesis suggests that a chronic inflammatory reaction at the site of injection provides a trigger for subsequent malignant transformation.

Irritant Inflammation Cancer!

Postinflammatory sarcoma in cats.
Vet J, 2011 May;188(2):136-41.

J Feline Med Surg, 2015 Jul;17(7):606-13.

Soft Tissue Sarcomas

Individual Susceptibility?

Genetic Predisposition?

Oncogene Expression

Vet J, 2011 May;188(2):136-41.

Mutational analysis of tumor suppressor gene p53 in feline vaccine site-associated sarcomas.
Am J Vet Res 61[10]:1277-81 2000

ISS: Below Knee/Elbow

Leukemia Left Rear

Rabies Right Rear


FVRCP Right Front

Intra-nasal



Soft Tissue Sarcomas

How do We Stage the Patient?



J Feline Med Surg, 2015 Jul;17(7):606-13.

Soft Tissue Sarcomas: Staging

- **Tissue** Diagnosis
 - Biopsy, Biopsy, Biopsy!
- **Location** of Cancer
 - 10-28% Metastases
- **Condition** of Patient
 - Anemia, Renal Disease?



J Feline Med Surg. 2015 Jul;17(7):606-13.



Prognostics: Histology

- 25%, Grade I
 - Recurrence: 25%
- 47.7%, Grade II
 - Recurrence: 50%
- 27.3%, Grade III
 - Recurrence: 75%

Feline vaccine-associated fibrosarcoma: morphologic distinctions. Vet Pathol. 2002;39(1):33-41.



Question!

- What is the metastatic rate of soft tissue sarcomas?
 - 1. 2-7%
 - 2. 10-28%
 - 3. 70-92%

© GK Ogilvie 2016 J Feline Med Surg. 2015 Jul;17(7):606-13.



Soft Tissue Sarcomas

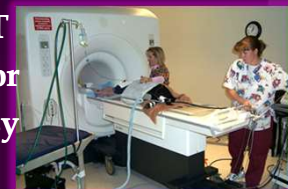Metastatic Rate:
10-28%

© GK Ogilvie 2016 J Am Vet Med Assoc. 2000 Jan 1;216(1):58-61.



Soft Tissue Sarcomas: Staging


- CBC, Biochem, UA, T4, FeLV/FIV
- Chest Rads/CT
- CT/MRI Tumor
- PRE-OP Biopsy



© GK Ogilvie 2016 J Feline Med Surg. 2015 Jul;17(7):606-13.



Stage the Patient



CT vs PE: 2X Difference
 Vet Radiol Ultrasound: 2000;41:575
 Vet Comp Oncol: 2015 Sep 14.


Soft Tissue Sarcomas

Best Treatments?



© GK Ogilvie 2016 *J Feline Med Surg* 2015 Jul;17(7):606-13.


STS: Quoidmodality Therapy



© GK Ogilvie 2016

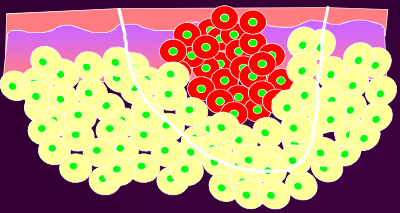
Soft Tissue Sarcomas

Surgery!



© GK Ogilvie 2016 *J Feline Med Surg* 2015 Jul;17(7):606-13.

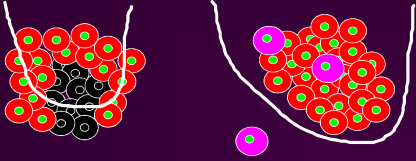
Fundamental of Surgical Cure



Surgery is the primary treatment for LOCALIZED neoplasia

© GK Ogilvie 2016

Fundamental Causes of FAILED Surgical Treatment...




Incomplete Excision
 Surgery is the primary treatment for LOCALIZED neoplasia

SKIP Metastasis

© GK Ogilvie 2016

**NEVER,
EVER: *Shell*
Out, *Peel*
Out, *Cut*
Through, Or
Otherwise
Mutilate
CANCER!!**

© GK Ogilvie 2016

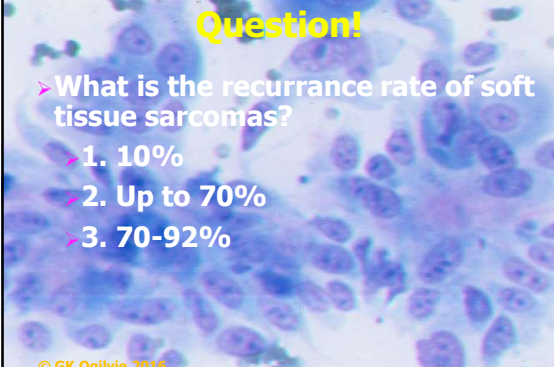


Question!

➤ What is the recurrence rate of soft tissue sarcomas?

- 1. 10%
- 2. Up to 70%
- 3. 70-92%

© GK Ogilvie 2016 J Feline Med Surg. 2015 Jul;17(7):606-13.



Soft Tissue Sarcomas


➤ **Surgery**

➤ **Aggressive Surgery**

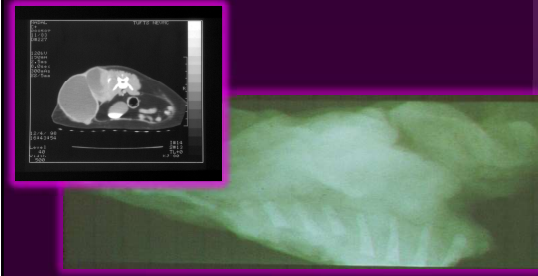
➤ **Up to 70% Failure Rate!**

Vet J. 2011 May;188(2):136-41.


© GK Ogilvie 2016 J Feline Med Surg. 2015 Jul;17(7):606-13.



Soft Tissue Sarcomas



© GK Ogilvie 2016 J Feline Med Surg. 2015 Jul;17(7):606-13.



Soft Tissue Sarcomas



Commandments...

© GK Ogilvie 2016



Soft Tissue Sarcomas

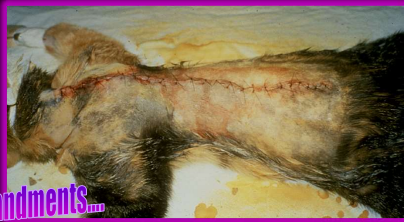➤ **Big, Wide, Deep, 1st Surgery**



© GK Ogilvie 2016 J Feline Med Surg. 2015 Jul;17(7):606-13.



Soft Tissue Sarcomas

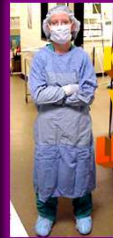

Commandments...

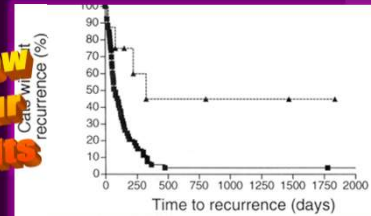
© GK Ogilvie 2016 J Feline Med Surg. 2015 Jul;17(7):606-13.



Soft Tissue Sarcomas



Know Your Limits



© GK Ogilvie 2016




Outcome following surgical removal of nonvisceral STS in cats: 42 cases

- Median survival (ST) time 608 days
 - 24 cats were still alive
- Median ST longer < 2 cm vs > 2 cm.
- Median ST Fibrosarcoma > Fibrous Histiocytoma

J Am Vet Med Assoc. December 2005;227(12):1955-7



The 5 cm Margin



© GK Ogilvie 2016



STS: Surgery 5 cm Margin

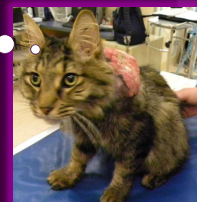- Radical excision with 5 cm margins for treatment of feline injection-site sarcomas: 91 cases (1998-2002).
 - Median ST 901 days, 14% recurrence, 20% metastasis after surgery.

J Am Vet Med Assoc. 2011 1;239(1):97.



Soft Tissue Sarcomas

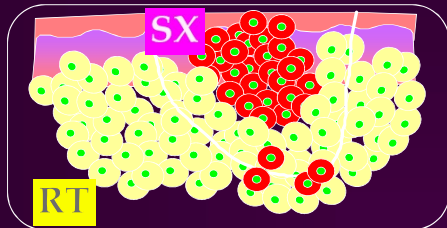
Radiation!



© GK Ogilvie 2016 J Feline Med Surg. 2015 Jul;17(7):606-13.



Radiation Therapy



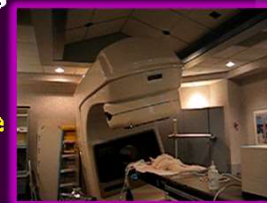© GK Ogilvie 2016 J Feline Med Surg. 2015 Jul;17(7):606-13.



Radiation Therapy

Important Points

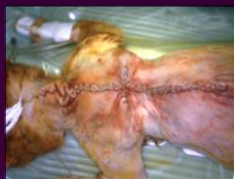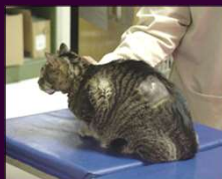- Surgical scar: contaminated
- Side effects: size of the radiation field



© GK Ogilvie 2016 J Feline Med Surg. 2015 Jul;17(7):606-13.



Radiation Therapy



© GK Ogilvie 2016 J Feline Med Surg. 2015 Jul;17(7):606-13.



STS: Surgery + Radiation

- RT for 73 cats with vaccine-associated sarcoma: Curative RT/clean; Coarse fractionated RT/dirty margins
 - Curative: Median ST 43 months & median PFI 37 months
 - Course: Median ST 24 months & median PFI 10 months

Vet Comp Oncol. 2009;7(1):54.



STS: Surgery + Radiation

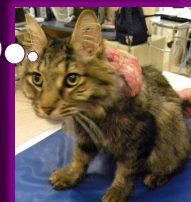- Radiotherapy and surgery for feline soft tissue sarcoma.
 - Median ST 520 days, 1 & 2-year survival rates of 61.6%, 41.6%.
 - Median ST 310, 705 d pre vs post Sx
 - Median ST 308, 760 d with and without anemia (PCV<25%)

Vet Radiol Ultrasound. 2009;50(6):669.



Soft Tissue Sarcomas

Chemo-immune-therapy!



© GK Ogilvie 2016 J Feline Med Surg. 2015 Jul;17(7):606-13.



Question!

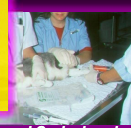
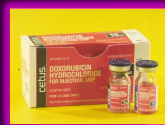➤ Which ONE of the below defines the MOST effective chemotherapy for STS?

- 1. Vincristine
- 2. Dactinomycin
- 3. Doxorubicin
- 4. Cisplatin

© GK Ogilvie 2016 J Feline Med Surg. 2015 Jul;17(7):606-13.



Soft Tissue Sarcomas



1 mg/kg q3 wks X 5

Combined Doxorubicin and Cyclophosphamide Chemotherapy for Nonresectable Feline Fibrosarcoma
J Am Anim Hosp Assoc 36[5]:416-421 2000
50% Response Rate, Median ST 288 Days

Liposome-encapsulated doxorubicin (Doxil) and doxorubicin in the treatment of vaccine-associated sarcoma in cats.
J Vet Intern Med. 2002;16(6):726-31

Surgery: 93 Days; Surgery + doxorubicin: 388 Days



STS RT/Liposomal Doxorubicin

- Concomitant liposomal doxorubicin and daily palliative radiotherapy in advanced feline soft tissue sarcomas.
- Median 5 dosages RT (20 Gy) + Doxil
- 5 PR, 2 CR, Median 237 Days
- PFS: 324 days

Vet. Radiol Ultrasound. 2010 51(3):349.



Question!

➤ Which is TRUE about metronomic therapy?

- 1. It is not effective
- 2. It used cytotoxic high dosage chemotherapeutic agents
- 3. It may result in rapid tumor reduction
- 4. It is antiangiogenic

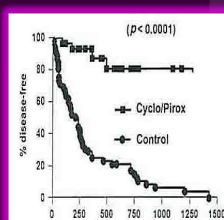
© GK Ogilvie 2016

Metronomic Chemo

➤ Soft Tissue Sarcoma

- Cyclophosphamide
- 10 mg/m² q48 h
- Piroxicam
- 0.1 mg/kg q48 h
- DHA
- 30 mg/kg q24 h

© GK Ogilvie 2016



Question!

➤ Has immunotherapy been *proven* to effectively treat soft tissue sarcomas?

- 1. No
- 2. Makes the Disease Worse
- 3. Yes

© GK Ogilvie 2016

Immunotherapy

- **Reduced Tumor Recurrence**
 - Gene Therapy: IL-2
 - Gene Therapy: GM-CSF, IL-2, IFN-Gamma
 - Recombinant fIL-2
 - Canarypox IL-2



© GK Ogilvie 2016

Local immunotherapy of spontaneous feline fibrosarcomas using recombinant poxviruses expressing Interleukin 2 (IL2).

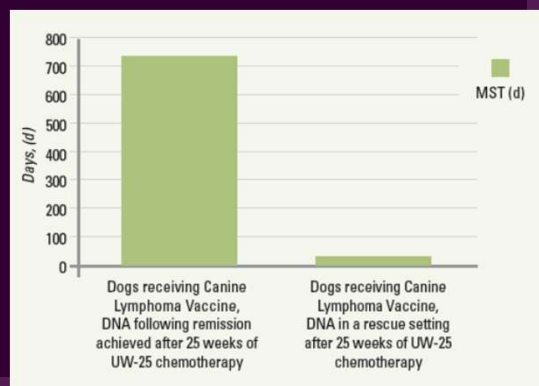
- **Recurrence Rate**
 - Surgery + RT = 61%
 - Surgery + rPoxvirus/ fIL-2 = 28%
 - 6 Injections @ Tumor Site
 - Canarypox Vector Enters fCells
 - IL-2 Produced, Induction of T-Lymphocytes & NK Cells

Journal of Feline Medicine and Surgery 2012; 26: 2126-32.

Adjuvant immunotherapy of feline injection-site sarcomas with the recombinant canarypox virus expressing feline interleukin-2 evaluated in a controlled monocentric clinical trial when used in association with surgery and brachytherapy

- **Three Groups:**
 - Surgery+RT+injections days 0 (prior to RT), 7, 14, 21, 35, 49.
- **Median Time to Relapse**
 - Control: 287 days
 - ALVAC IL-2 Low Dose: >730 days

Trials in Vaccinology Vol 4, 2015, 1-8.



STS: Quoidmodality Therapy

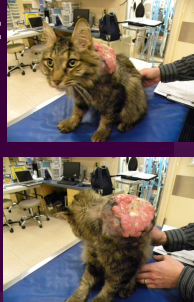

STS: Bi/Trimodality Therapy



Piroxicam 0.1 mg/kg q48hrs

- Don't Let Them Hurt
- Hospice Care
 - Analgesia, Appetite



© GK Ogilvie 2016

FISS/STS: Critical Points

- **Record** anatomic location, shape, size
- **Manage** every mass as if malignant
- **Biopsy** mass prior to surgical excision
- **Stage** patient prior to surgical excision
- **Excise** deep/wide, submit for histopath



Commandments...

© GK Ogilvie 2016

